

# Seven-Month Weaning Process in Primary Hypothyroidism with Myxedema Coma and Respiratory Failure — A Case Report

Kuo-Sheng Fan, Jin-Duo Wang, Yen-Hsien Lee,  
Chin-Sung Kuo<sup>1</sup>, and Chun-Liang Lai

*Divisions of Pulmonology and <sup>1</sup>Endocrinology,  
Buddhist Dalin Tzuchi General Hospital, Dalin, Chiayi, Taiwan*

## Abstract

Hypothyroidism is common, often overlooked, readily diagnosed by laboratory testing, and eminently treatable. The clinical presentation varies from a subclinical form with insignificant symptoms to the most extreme form of myxedema coma with respiratory failure. Myxedema coma is rare but potentially lethal, the symptoms and signs are many and are often insidious. Here we report a rare case of a 68 years old male with primary hypothyroidism with myxedema coma and respiratory failure. The treatment included meticulous chest care and oral L-thyroxine replacement therapy. Despite dramatic clinical response, it took seven months for the patient to be completely liberated from mechanical ventilation. ( *J Intern Med Taiwan* 2005; 16: 95-99 )

**Key Words :** Hypothyroidism, Myxedema coma, Respiratory failure, Weaning

## Introduction

Hypothyroidism is the most common pathological hormone deficiency, the variety of end-organ effects and wide range of disease severity make it an elusive clinical entity<sup>1</sup>. The early recognition of hypothyroidism remains a challenge, especially when

the decline in thyroid function is gradual. In some instances, the manifestations were simply attributed to the effects of aging in the elderly<sup>2</sup>. Infrequently, hypothyroidism may progress to myxedema coma, a state characterized by defective thermoregulation and altered mental status to the point of coma after a precipitating event<sup>3</sup>. Here we report a case of primary

---

Correspondence and requests for reprints : Dr. Chun-Liang Lai

Address : Division of Pulmonology, Buddhist Dalin Tzuchi General Hospital, 2 Min-Sheng Road, Dalin, Chiayi 622 Taiwan

hypothyroidism with myxedema coma and respiratory failure, the diagnosis was delayed two months after the initial presentation. The clinical symptoms and signs responded dramatically to oral L-thyroxine replacement therapy. However, it took seven months for the patient to be completely liberated from mechanical ventilation.

### Case report

A 68-year-old male was transferred to our hospital with respiratory failure and altered consciousness of two months' duration. His medical history was significant for a degenerative intervertebral disc disease, chronic renal insufficiency, and a paralytic ileus episode that required hospitalization. For the previous ten years, he had suffered from severe hearing impairment.

Two months prior to admission, the patient was found to have severe dyspnea and altered consciousness. He was brought to a nearby hospital where he was endotracheally intubated and mechanical ventilation was instituted. Because of persistent respiratory failure with difficult weaning, he was transferred to our respiratory care ward.

On examination, the patient was pale, edematous, lethargic and appeared chronically ill. He was in a deeply stuporous state and was barely arousable. The temperature was 34.7 °C, the pulse was 70/min, and blood pressure was 153/91 mmHg. He had a slightly protruding tongue. There was a tracheostomy in situ and the patient was on assisted breathing. The heart sounds were distant, and sonorous rhonchi and fine crackles were heard on both lung fields. The abdomen was soft and slightly distended, the bowel sounds were normoactive. There was general nonpitting edema and the skin appeared coarse and dry. There was diffuse muscle weakness and wasting, and general areflexia. A chest radiograph with portable machine showed exaggerated lung marking with no obvious infiltration (Fig. 1). An echocardiogram revealed a mildly dilated left ventricle (LV), concentric LV hypertro-



Fig. 1. Chest radiograph with portable machine. There is exaggerated lung marking with no obvious infiltration.



Fig. 2. Electrocardiogram showing nonspecific T wave changes and prolonged QT interval.

phy, adequate LV performance, and possibly impaired LV relaxation. The electrocardiogram showed nonspecific T wave changes and prolonged QT interval (Fig. 2). A thyroid sonogram revealed atrophic change in both lobes with no notable parathyroid gland.

Routine laboratory check-ups, including thyroid function test were performed (Table).

The B12, folate, prolactin, parathyroid hormone, and cortisol levels were normal, as were the serum and urine protein electrophoresis. Tests for anti-thyroglobulin antibody and anti-microsomal antibody were negative.

Weaning parameters on admission were satisfactory, with a maximum inspiratory pressure of -30 cm H<sub>2</sub>O and a maximum expiratory pressure of +60 cm H<sub>2</sub>O, an average tidal volume of 422 ml, and a minute ventilation of 9.72 L. The respiratory rate/tidal volume ratio was 54.5/L.

Therapy with oral L-thyroxine 50 mcg/day was

Table. Selected Laboratory Data

Variable	On admission	After 2 months	After 5 months	After 7 months
Hemoglobin ( g/dL )	7.6	8.8	6.8	8.7
MCV ( fL )	98.6	101	-	94.9
Na ( mmol/L )	114.5	131.5	133.5	129.3
BUN ( mg/dL )	42	93	52	55
Creatinine ( mg/dL )	3.7	4.4	4.5	4.0
Calcium ( mmol/L )	3.16	3.10	3.24	2.48
Cholesterol ( mg/dL )	295	-	-	-
Triglyceride ( mg/dL )	332	-	-	-
Phosphorus ( mg/dL )	4.9	-	5.4	5.2
Magnesium ( mg/dL )	5.4	3.4	-	3.5
Bicarbonate ( mmol/dL )	23.1	27.2	-	20.0
TSH ( mU/L )*	73	12.75	1.22	-
free T4 ( ng/dL )**	0.3	0.83	1.00	-

\*Thyroid-stimulating hormone, normal range 0.35-5.5 mU/L

\*\*free Thyroxine, normal range 0.7-1.8 ng/dl

started immediately after the diagnosis was made and the ventilator setting was soon shifted from the initial assist/control mode to pressure support mode starting at a level of 10 cm H<sub>2</sub>O. The clinical condition improved dramatically thereafter.

One week after treatment, the consciousness became clearer, and the skin turgor increased. Spontaneous breathing trials were started at this time, and the L-thyroxine dosage was increased to 100 mcg/day.

Two months after treatment, the patient was able to sustain a spontaneous breathing trial for a few days but would end up in CO<sub>2</sub> narcosis. The follow-up serum FT4 level was within normal range while the serum TSH level was still higher than normal.

Three months after treatment, the L-thyroxine dosage was increased to 150 mcg/day.

Five months after treatment, the serum TSH and free T4 levels were within normal ranges.

Seven months after treatment, the patient was successfully liberated from mechanical ventilation. The follow-up chest film and electrocardiogram showed no significant change (Fig. 3 & 4).

## Addendum

The patient died of an unexpected heart attack two weeks after weaning. No autopsy was performed.

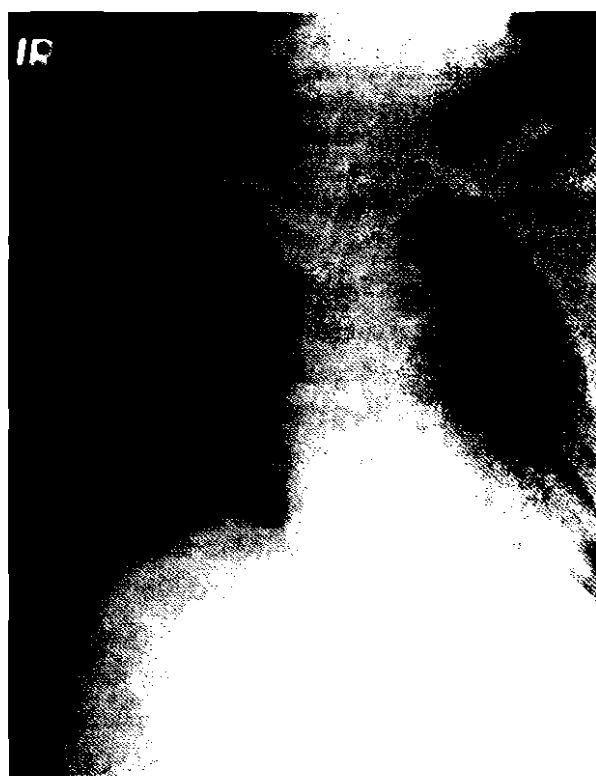

Fig.3. Follow-up chest film near the end of weaning. There is mild perihilar pulmonary congestion indicating fluid overloading; and abdominal gaseous distention.

## Discussion

There is a broad clinical spectrum of hypothyroidism, extending from a mild subclinical form at one end to an extreme myxedema coma at the other.

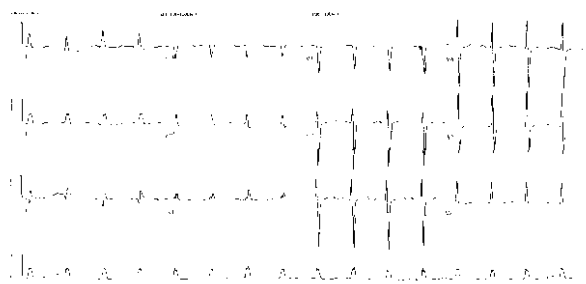


Fig.4. ECG taken at the end of weaning, there is no significant change as compared with the initial recording.

Subclinical hypothyroidism is common, with a world wide prevalence of 1 to 10 percent, the highest among old age women and approaching 20% in some reports<sup>4,5</sup>. Patients at risk include treated hyperthyroidism, a history of neck irradiation, postpartum thyroiditis, and certain autoimmune disorders. Worldwide, dietary iodine deficiency remains an important cause of endemic goiter and thyroid dysfunction. Myxedema coma is a rare and the most severe form of hypothyroidism that is associated with significant mortality rates of up to 80%<sup>6</sup>. Higher mortality is associated with older age, bradycardia, hypothermia, and the presence of complicating factors such as sepsis, hypotension, myocardial infarction, left ventricular failure, respiratory failure and gastrointestinal bleeding<sup>6,7</sup>.

Hypothyroidism alters ventilation in two ways<sup>18</sup>. The first is diminished central response to hypoxia and hypercapnia, resulting in respiratory acidosis. The second is a propensity for respiratory alkalosis, especially after the initiation of overaggressive mechanical ventilation. Presumed causes include a reduced basal metabolic rate and diminished CO<sub>2</sub> production. In addition to altering ventilation, hypothyroidism also causes weakness of the diaphragm and other respiratory muscles; both contribute to hypoxia and hypercapnia.

Anemia is common in hypothyroidism and is often moderate<sup>9</sup>. Macrocytosis is a feature of concomitant folate or B12 deficiency; normocytic anemia is probably secondary to depressed erythropoi-

tin synthesis while microcytic anemia may be due to iron deficiency, especially in women with menorrhagia<sup>9</sup>.

The causes of hyponatremia and electrolyte abnormality in our patient are multifactor; including impaired free water excretion and syndrome of inappropriate antidiuretic hormone secretion<sup>1</sup>, and a complex interplay of the underlying disease, chronic renal insufficiency, prolonged immobilization, and dietary inadequacy. Anemia, hypercalcemia, and hyponatremia persisted in our patient even after the weaning was completed.

Care must be taken in treating patient with myxedema coma. External heating is not recommended because of vasodilation and possible subsequent vascular collapse. Rapid wash out of CO<sub>2</sub> may result in alkalosis and so dead space may be needed at times<sup>3</sup>. Overt hypothyroidism has long been known to be associated with hypercholesterolemia, though the relationship between subclinical hypothyroidism and the later development of atherosclerosis is unclear<sup>10</sup>. Thyroxine treatment of hypothyroid patients might exacerbate myocardial ischemia in those with underlying coronary artery disease due to positive inotropic and chronotropic effects of thyroid hormone<sup>1</sup>. Rapid restoration of thyroid hormone carries the risk of arrhythmias or sudden death and intravenous T3 should be reserved for younger patients with no known coronary artery disease or arrhythmias<sup>8</sup>. The undesirable outcome in our patient further emphasizes the importance of early recognition of the underlying coronary artery disease. And continuing electrocardiographic monitoring, even after weaning, is strongly recommended.

In patients with primary hypothyroidism, the TSH level should be lowered to about the midpoint of the normal range. In secondary hypothyroidism, the goal is to achieve a normal FT4 level<sup>2</sup>.

Given the lack of imminent life threatening conditions, our patient was treated less aggressively. Obvious clinical improvement was observed one

week after treatment. However, the respiratory insufficiency recovered more slowly. Complete liberation from mechanical ventilation was achieved seven months after treatment.

## Conclusion

Hypothyroidism is common and is easily overlooked and so should be included in the differential diagnosis of any respiratory failure, especially among the elderly or those with persistent hypothermia or cardiac dysfunction.

Our case highlights the need for continued meticulous care and electrocardiographic monitoring in the profoundly hypothyroid patient even after the commencement of treatment. It also demonstrates the prolonged duration of respiratory failure in myxedema coma. Complete recovery may take up to seven months.

## References

1. Roberts CG, Ladenson PW. Hypothyroidism. *Lancet* 2004; 363: 793-803.
2. Guha B, Krishnaswamy G, Peiris A. The diagnosis and management of hypothyroidism. *South Med J* 2002; 95: 475-80.
3. Behnia M, Clay AS, Farber MO. Management of myxedematous respiratory failure: review of ventilation and weaning principles. *Am J Med Sci* 2000; 320: 368-73.
4. Cooper DS. Clinical practice. Subclinical hypothyroidism. *N Engl J Med* 2001; 345: 260-5.
5. Canaris GJ, Manowitz NR, Mayor G, et al. The Colorado thyroid disease prevalence study. *Arch Intern Med* 2000; 160: 526-34.
6. Urquhart AD, Rea TM, Lawson LT, et al. A new complication of hypothyroid coma: neurogenic dysphagia: presentation, diagnosis, and treatment. *Thyroid* 2001; 11: 595-8.
7. Jordan RM. Myxedema coma. Pathophysiology, therapy, and factors affecting prognosis. *Med Clin North Am* 1995; 79: 185-94.
8. Ringel MD. Management of hypothyroidism and hyperthyroidism in the intensive care unit. *Crit Care Clin* 2001; 17: 59-74.
9. Mitchell JM. Thyroid disease in the emergency department. Thyroid function tests and hypothyroidism and myxedema coma. *Emerg Med Clin North Am* 1989; 7: 885-902.
10. Helfand M. Screening for subclinical thyroid dysfunction in non-pregnant adults: a summary of the evidence for the U.S. Preventive services task force. *Ann Intern Med* 2004; 140: 128-41.

# 七個月的呼吸器脫離期於甲狀腺低下併黏液水腫昏迷—病例報告

范國聖 王金鐸 李彥憲 郭錦松<sup>1</sup> 賴俊良

佛教慈濟綜合醫院大林分院 內科部 胸腔內科 <sup>1</sup>新陳代謝科

## 摘要

甲狀腺功能不足很常見，診斷並不難也很容易治療，但卻常常為人所忽略。其臨床表現由最輕微的無症狀到最極端的黏液水腫昏迷併呼吸衰竭皆有可能。黏液水腫很罕見但有可能致命，其臨床症狀常呈非特異性且多樣化。我們在此報告一68歲男性患有原發性甲狀腺功能不足合併黏液水腫昏迷及呼吸衰竭的個案。其治療包括積極呼吸治療及口服甲狀腺素。雖然臨床治療效果很明顯，但卻需治療七個月後才得以成功脫離呼吸器。